

**PATIENT**  
Victoria Clements

**PRESENTING CLINICAL SIGNS**

History: Victoria is referred for a heart murmur noted in February. She needs a dental procedure. Doing well clinically. Good appetite and very good energy. Grade II/VI sternal murmur. BP: 120-130mmHg. \*No sedation.

**SPECIES**  
Feline

**ECHOCARDIOGRAM FINDINGS**

2D, m-mode, color flow and Doppler imaging is available.

**BREED**  
DSH

**Left ventricle:** The LV diameter is normal with adequate myocardial function. The LV wall thicknesses are normal. The papillary muscles are normal. The endocardium appears normal.

**SEX**  
Female Spayed

**Left atrium:** The left atrium is normal in dimension. No obvious spontaneous contrast or thrombi seen.

**AGE**  
2.5 years

**Mitral valve:** The mitral valve is normal in structure and mobility. No obvious systolic anterior motion is seen. No MR.

**WEIGHT**  
7.1lbs

**Aortic valve/Aorta:** The aortic valve is normal in morphology and mobility. Normal aortic outflow velocity; laminar flow. No aortic insufficiency.

**Right ventricle:** Normal right ventricular diameter and morphology indicating no overt evidence of pulmonary arterial hypertension.

**Right atrium:** The right atrium is normal in dimension.

**Tricuspid valve:** The tricuspid valve appears normal with no tricuspid regurgitation.

**Pulmonic valve/Pulmonary artery:** The pulmonic valve is normal in morphology and mobility. No pulmonic insufficiency. Normal RVOT velocity; laminar flow.

**Pericardium/other:** No pericardial or pleural effusion noted. No obvious cardiac masses.

**Heart rhythm:** ECG reveals a sinus rhythm with an average HR of 188bpm.

**INTERPRETED BY**

Maggie Machen  
Lamy, DVM  
DACVIM (Cardiology)

**2-Dimensional Measurements**

Ao diam (cm)	0.84
LA diam (cm)	1.0
LA:Ao (Swe)	1.2
IVS thickness (cm)	0.38
LVID diastole (cm)	1.5
PW thickness (cm)	0.39
LVID systole (cm)	0.7
FS (%)	56

**Doppler Measurements**

PV Vmax (m/s)	0.84
AoV Vmax (m/s)	1.1
MR Vmax (m/s)	NA
TR Vmax (m/s)	NA
TR PG (mmHg)	NA

**IMAGING PERFORMED BY**

Pamela Harrigan,  
RDCS

**INTERPRETATION OF THE FINDINGS**

Overtly normal cardiac structure and function. The LV wall thickness is normal and there is no evidence of elevated left atrial pressure. No obvious congenital defects are seen at this time. No cause for the murmur is identified in this study, making it likely physiologic in origin (i.e., secondary to tachycardia, volume changes, etc.).

**HOSPITAL NAME**

Mass Veterinary  
Specialty Services

**REFERRING VET**

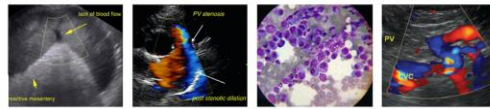
Dr. Masloski

**RECOMMENDATIONS**

- Given these findings, no medications are indicated.
- No cardiac contraindication for general anesthesia.
- Monitor for any clinical evidence of cardiac compromise, including respiratory changes and/or signs of a blood clot event (paralysis, neurologic changes, etc.).

**INVOICE**  
21468

**DATE**  
10/12/21



**PATIENT**

Victoria Clements

**PLAN**

- Recommend recheck echocardiogram in 1 year to reassess murmur origin and screen for development of disease the pre-existing murmur may mask.

**SPECIES**

Feline

**BREED**

DSH

**SEX**

Female Spayed

**AGE**

2.5 years

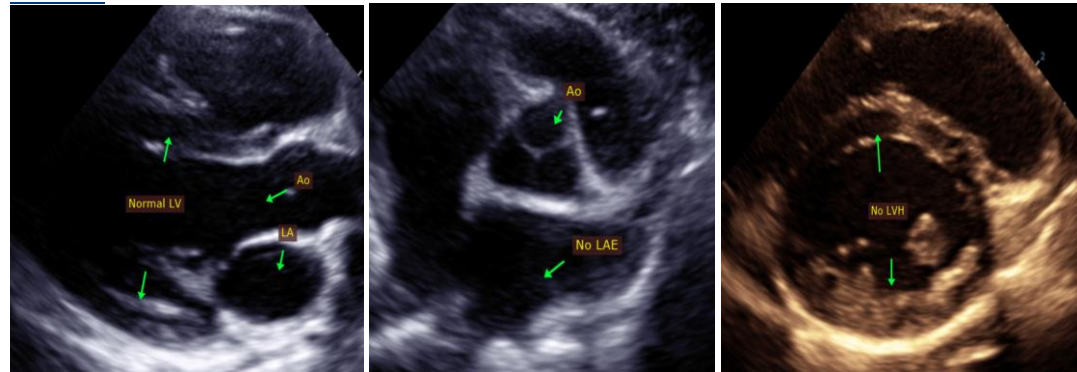
**WEIGHT**

7.1lbs

**INTERPRETED BY**

Maggie Machen  
Lamy, DVM  
DACVIM (Cardiology)

**IMAGES**



The information and recommendations provided are based on the images presented by the referring veterinarian. No evaluation can be communicated regarding pathology that was not visible in the image/video clips provided.

Thank you for this referral. This report was generated using transcription software, and minor dictation errors may be present. If the clinical or image interpretation does not parallel your findings or if I can be of any further assistance, please contact me.

**Maggie Machen Lamy, DVM**

**Diplomate of the American College of Veterinary Internal Medicine (Cardiology)**

info@sonopath.com

**Echocardiogram performed by:** Pamela Harrigan, RDCS

Pet Animal Ultrasound Service (4paus.com)

**IMAGING PERFORMED BY**

Pamela Harrigan,  
RDCS

**HOSPITAL NAME**

Mass Veterinary  
Specialty Services

**REFERRING VET**

Dr. Masloski

**INVOICE**

21468

**DATE**

10/12/21